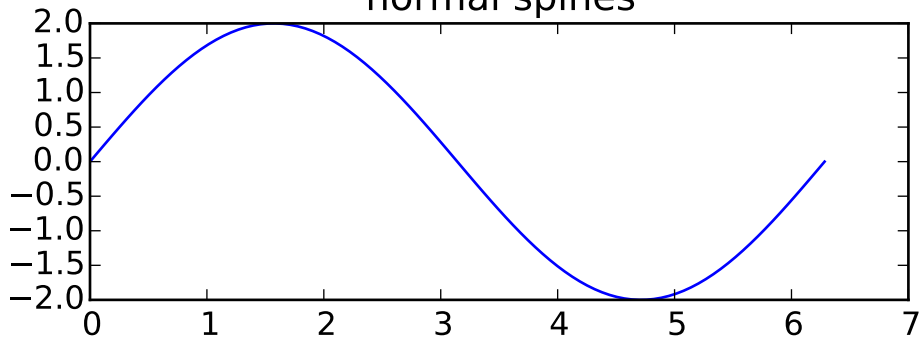


normal spines



bottom-left spines

